

CASE REPORT**Graves' Disease Affecting one Thyroid lobe (Unilateral Graves' Disease):
Case Report**

Al Juhanni N., Wagieh Sh. and Al Ghamdi H.

Oncology center and endocrinology* department, King Abdel Aziz Hospital and oncology center,
Jeddah, KSA**ABSTRACT**

We report a 63-year-old male who was referred to nuclear medicine unit for thyroid scanning with provisional diagnosis of Graves' disease. The patient presented to endocrinology clinic few days before referral with clinical features of heart failure and bilateral exophthalmos, with no history of previous thyroid surgery or anti-thyroid medication. Clinically there was diffuse enlargement of the right thyroid lobe with no definite nodules and no palpable left lobe. His thyroid hormonal profile revealed evidently elevated free T3 and free T4 [12.9 pmol/L (N: 3.1-6.8) and 38.4 pmol/L (N: 12-22) respectively] associated with markedly suppressed serum TSH level (< 0.005 mIU/ml). Antimicrosomal antibodies (thyroid peroxidase antibodies) were positive with negative antithyroglobulin antibodies. Tc99m pertechnetate thyroid scan revealed diffuse enlargement of the right lobe with intense homogenous tracer uptake pattern, and more intense tracer uptake in its mid substance due

to thicker thyroid tissue rather than true nodule. The upper and lower poles showed intense uptake, more than would be expected for such thinner parts of the lobe. On the other hand the left lobe was not functionally suppressed. It is of average size with evidently less tracer uptake in a homogenous pattern, again it harbors no nodules (**Fig1**). The total thyroid uptake level was 11.5%, the right lobe uptake was 9.9% while left lobe uptake was 1.6% (**Fig1**). High resolution thyroid ultrasound (**Fig2**) revealed average size of the left lobe (14x12x34mm) with decreased echogenicity and no increase in vascularity. On the other hand, the right lobe is enlarged (22x24x46) with coarse texture and no nodules. The combined scintigraphic and sonographic data exclude the presence of toxic nodule occupying the whole right thyroid lobe. The patient was diagnosed as Graves' disease affecting only the right thyroid lobe (unilateral Graves' disease).

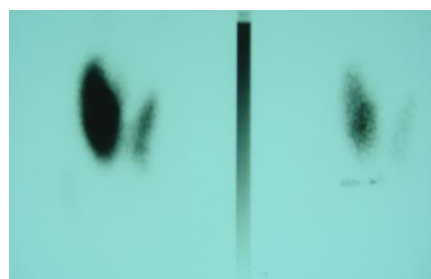
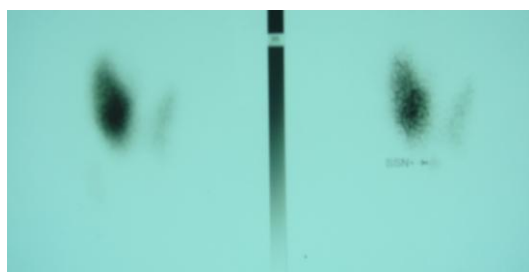


Fig1: Tc99m thyroid scan showing enlarged right thyroid lobe with intense tracer uptake and no nodules and normal scintigraphic appearance of the left lobe. Total thyroid uptake =11.5%, right lobe =9.9%, Left lobe =1.6%.

Corresponding Author

Sherin Wagih, MD.

E-mail: dr_sherinwagih@hotmail.com

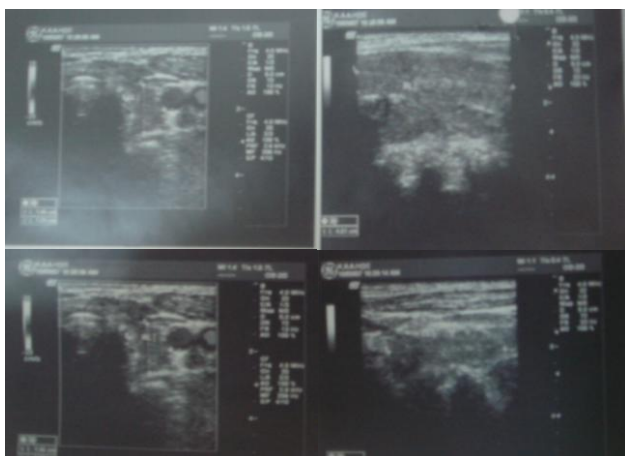


Fig2: High resolution US: No nodules in the enlarged right thyroid lobe that shows coarse texture with normal sonographic appearance of the left lobe.

DISCUSSION

Robert Graves, a distinguished Irish physician and prolific medical author, gave his name to an autoimmune disorder of the thyroid gland in 1830s. It is usually characterised by hyperthyroidism due to circulating autoantibodies although the whole spectrum of thyroid function may be found in these patients. Thyrotoxicosis and thyroid eye disease frequently occur together (both are required for the strict clinical diagnosis of Graves' disease) but the latter can be mild and difficult to detect. In Graves' disease, B and T lymphocyte-mediated autoimmunity are known to be directed at four well-known thyroid antigens: thyroglobulin, thyroid peroxidase, sodium-iodide symporter, and the thyrotropin receptor. However, the thyrotropin receptor itself is the primary autoantigen of Graves' disease and is responsible for the manifestation of hyperthyroidism^(1,2).

In Graves' disease the thyroid gland is under continuous stimulation by circulating autoantibodies against the thyrotropin receptor, and pituitary thyrotropin secretion is suppressed because of the increased production of thyroid hormones. The stimulating activity of thyrotropin receptor antibodies is found mostly in the immunoglobulin G1 subclass. These thyroid-stimulating antibodies cause release of thyroid hormone and thyroglobulin that is

mediated by 3',5'-cyclic adenosine monophosphate (cyclic AMP), and they also stimulate iodine uptake, protein synthesis, and thyroid gland growth. The anti-sodium-iodide symporter, antithyroglobulin, and antithyroid peroxidase antibodies appear to have little role in the etiology of hyperthyroidism in Graves' disease. However, they are markers of autoimmune disease against the thyroid (2, 3).

Iodine transport is mediated by a specific sodium dependent iodide symporter (NIS) located in the basolateral membrane of thyroid follicular cells. NIS cotransports two sodium ions along with one iodide ion. In Graves' disease there is abundant NIS immunoreactivity at the basolateral aspect of most thyroid follicular cells which is consistent with clinical observation of diffuse increase uptake of iodide (and thus of free Tc99m pertechnetate) in active Graves' thyrotoxicosis^(3,4).

Thyroid Peroxidase (TPO) antibodies (In the past, they were referred to as antimicrobial antibodies) work against thyroid peroxidase, an enzyme that plays a part in the T4-to-T3 conversion and synthesis process. TPO antibodies can be an evidence of thyroid tissue destruction, such as in Hashimoto's disease, less commonly, in other forms of thyroiditis such as post-partum thyroiditis. It's estimated that TPO

antibodies are detectable in approximately 95 percent of patients with Hashimoto's thyroiditis, and 50 to 85 percent of Graves' disease patients. The concentrations of antibodies found in patients with Graves' disease are usually lower than in patients with Hashimoto's disease. For the patient of the current case report there was elevation of thyroid peroxidase antibodies. Testing for thyroglobulin antibodies (also called antithyroglobulin antibodies) is common in thyroid disorders. When patients diagnosed with Graves' disease are having high levels of thyroglobulin antibodies, this means that they are more likely to eventually become hypothyroid. Thyroglobulin antibodies are positive in about 60 percent of Hashimoto's patients and 30 percent of Graves' patients. In our patient the thyroglobulin antibodies were negative^(3,5).

In Graves' disease, usually thyroid lobe involvement and ophthalmopathy occur bilaterally, and thyroid scan reveals bilateral diffuse enlargement of both thyroid lobes with intense homogenous tracer uptake pattern all over the whole gland. Although unilateral Graves' ophthalmopathy is frequently seen, unilateral Graves' disease affecting one lobe of the thyroid gland is rarely encountered. In the literature there are some cases of unilateral Graves' disease but these occur in patients with aplasia of the contralateral lobe⁽⁶⁾. Ozaki et al⁽⁷⁾ treated eight patients with hemiplasia of the thyroid associated with Graves' disease. All were women and their chief complaints were goiter, exophthalmos, palpitation and edema. All eight patients underwent surgery for Graves' disease. The left lobe was absent in six cases and the right lobe in two, whereas the isthmus was absent in six cases and the pyramidal lobe in four. A total of 102 cases of hemiplasia of the thyroid have been reported in the world literature since 1970, with 32 of them consisting of hemiplasia associated with hyperthyroidism. Of these, the cause of hyperthyroidism was Graves' disease in 22 cases, an autonomously functioning thyroid nodule in seven, and thyrotoxic multinodular goiter in 3. The left lobe was absent in 19 cases while the right lobe was missing in 12, and laterality was unknown in 1 case. Other cases with hyperthyroidism with

involvement of one thyroid lobe were published but in all of them hyperthyroidism started post hemithyroidectomy due to goiter. So in all these cases the unilateral involvement was due to absence of the other lobe, either due to hemiplasia or hemithyroidectomy⁽⁷⁾.

Patients presenting with hyperthyroidism due to Graves' disease with unilateral involvement in a bilobed thyroid gland are rare and few cases were published in the literatures. In 1993, Sakata and his colleagues⁽⁸⁾ reported two patients with Graves' disease with unilateral uptake of isotope on Tc99m scan in one patient and on I-123 scan in the other. Both were treated by right hemithyroidectomy and after 27 and 8 months respectively, recurrent thyrotoxic symptoms occurred with enlargement of the remaining left lobe in both patients, it showed intense I-123 uptake in thyroid scan and both were controlled medically⁽⁴⁾.

In 1999, Dimai et al⁽⁹⁾ reported unilateral Graves disease in a 31 years old female. This was reported again in a 33 years old woman in 2004⁽¹⁰⁾ and in 39 years old male by Bolognesi and Rossi in 2006⁽⁶⁾. Interestingly, all cases reported in the literature, including ours, involve the right thyroid lobe. There is no actual explanation for this, yet it was suggested that the right lobe is usually larger than the left and more frequently affected by nodular and non nodular conditions⁽⁶⁾.

It might be speculated that interaction of only one lobe with antibodies may be caused by side to side differences of multifactorial origin. One reason might be local suppression of NIS gene expression and function which may be responsible at least in part for development of impaired radioiodine uptake by thyroid tissue, as it was published for Hashimoto thyroiditis, especially during early stages of hyperthyroidism. Another reason might be the isolated lymphatic drainage of each lobe, which may lead to different autoreactivity against the key thyroid autoantigens and thyroid stimulating hormone receptors (TSH-R). This in part would also support the hypothesis of Dimai et al⁽⁹⁾ who postulated that the side to side difference may be caused by bacterial or viral infection of the thyroid gland. In fact most thyroid infections are

due to lymphatic seeding and may lead to inhomogenous alteration of thyroid tissue^(10,11).

Finally, this report describes one of the rare cases of hyperthyroidism attributed to Graves' disease with unilateral involvement of the thyroid gland. The aetiology of this is still unclear and the most appropriate reason is the presence of inhomogenous local antigen expression, further studies are needed to clarify the exact underlying mechanism and etiology of this rare thyroid disorder.

REFERENCES

- 1) Yeung S-CJ., Habra M. and Chiu A.: eMedicine endocrinology: Graves' disease: follow-up ;April 2010.
- 2) Drexhage HA. : Autoimmunity and thyroid growth: Where do we stand? European journal of immunology;135:39-45,1996.
- 3) DeGroot JL. And Weetman PA.: Autoimmunity to the Thyroid Gland. In www.THYROIDMANAGER.ORG, Chapter 7, Updated January 2010.
- 4) DeLaVieja A., Dohan O and Levy O: Molecular analysis of the sodium/iodide symporter: Impact on thyroid and extrathyroid pathophysiology. Physiol rev; 80:1083-1105. 2000.
- 5) Mary Shomon: About. com: Thyroid disease: Thyroid blood tests; March 2007
- 6) Bolognasi M. and Rossi R.: Case history: unilateral Graves' disease. Thyroid, Vol. 16. Number 5, 493.2006.
- 7) Ozaki O., Ito K., Mimura T, Sugino K, Kitamura Y, Iwabuchi H. and Kawano M. :Hemiplasia of the thyroid associated with Graves' disease: Report of three cases and a review of the literature . Surgery today.vol24, Number 2 ,:164-169.1994.
- 8) Sakata S, Fuwa Y, Goto S, Fukui M, Yuasa H, Takuno H, Sarui H, Matsui I, Ogawa T, and Sassano N. :Two cases of Graves' disease with presentation of unilateral diffuse uptake of radioisotopes. Jour. Endocrinol Invest. 16 (11):903-907: 1993.
- 9) Dimai HP, Ramschak-Schwarzer S. and Lax S. : Hyperthyroidism of Graves' disease: evidence for only unilateral involvement in the thyroid gland in a 31 years old female patient. Jour. Endocrinol. invest., 22.215-219:1999.
- 10) Gratz S., Borth P, Arnold R, and Behr TM: Graves' disease with unilateral radioisotope uptake. Nuclearmedizin, 5; N1-N3, 2004.
- 11) Dayan DM and Daniels GH: Chronic autoimmune thyroiditis. N Engl J Med; 335:99-107, 1996.