

## CASE REPORT

### **Thallium 201 scanning can diagnose multiple recurrences in forearm implanted parathyroid tissue post total parathyroidectomy:**

**Salman AK., Wagieh S., Munshy AT. and Al Ghamdy H.\***

King Abdulla Medical City, Nuclear medicine department and Oncology Center\*

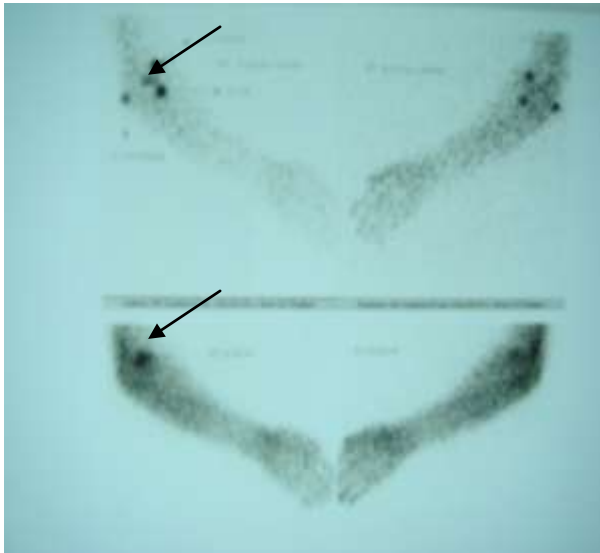
We report a case of a 48 years old male known to have chronic renal failure for more than 17 years. Patient was on regular haemodialysis for the last eleven years post failure of renal transplant due to graft rejection. Patient developed secondary hyperparathyroidism .He underwent total parathyroidectomy (surgical removal of the four parathyroid glands) with reimplantation of parathyroid tissue in the proximal right forearm in July 2009. Three months later, In November 2009, serum parathormone level (PTH) was elevated reaching up to 766pg/ml (N: 15-65 pg/ml) .Patient was operated upon for removal of the implanted tissue in the right forearm (no available preoperative diagnostic imaging modalities). Gross description in histopathology was two pieces of tissue representing two nodules each 2X1 cm. Microscopically, the picture was consistent with chief cell hyperplasia .Post operatively both serum calcium and parathormone levels were normalized (Jan.2010). First presentation to king Abdulla Medical city was in August 2010, patient presented with mildly tender small swelling in proximal right forearm associated with intermittent generalized bony pains. Laboratory data revealed hypercalcemia (serum calcium level: 3.4 mmol/L -N:2.1-2.5 mmol/L)with markedly elevated serum PTH level (2184pg/ml) . CT scan of right forearm revealed presence of a nodular enhancing lesion of 29X11.6X7.7 mm with well defined margin

in the site of implantation at lateral (radial) aspect of proximal right forearm just underlying the skin. Thallium201(TL201) scan revealed a well defined TL201 avid lesion located at lateral aspect of proximal right forearm just below the scar (**Fig1**). Besides, it revealed absence of any TL201 uptake that may represent overfunctioning parathyroid tissue neither in the neck nor in the mediastinum.(**Fig 2**) Patient was operated upon by removal of the lesion in the forearm for the second time (September2010). Histopathology proved to be parathyroid hyperplasia (**Fig3**). Post operative serum PTH level was still elevated (416.2 pg/ml) with persistent hypercalcemia (2.83 mmol/L). TL201 scan was repeated in January 2011. It revealed presence of small linear TL201 avid lesion in proximal right forearm (**Fig4**). Again, no TL201 avid lesions depicted in the neck or in mediastinum that may represent overfunctioning parathyroid tissue at normal anatomical sites of parathyroid glands nor at any expected ectopic site. The patient was reoperated upon with re-excision of the lesion in the right forearm for the third time. Again, Histopathology proved to be parathyroid hyperplasia. Serum parathormone level at 2 months post surgery (March 2011) was 20.2pg/ml(N:15-65),with normal serum calcium level 2.2mmol/L. Patient is under regular follow up with normal serum calcium and parathormone levels till September 2011.

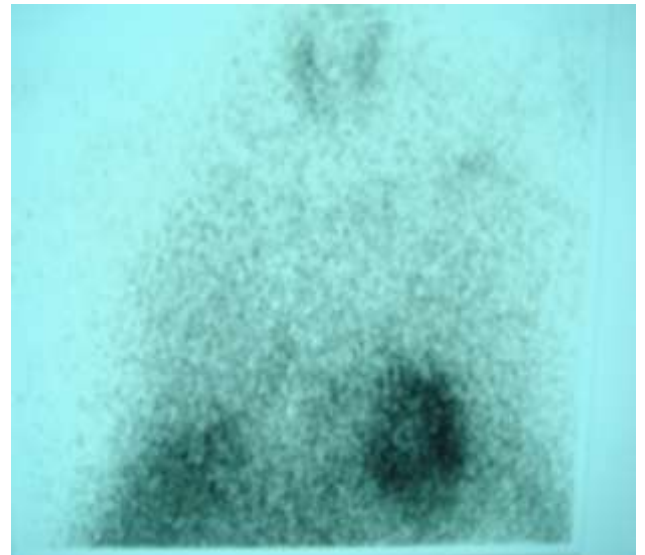
#### **Correspondence author:**

**Dr. Sherine Wagih**

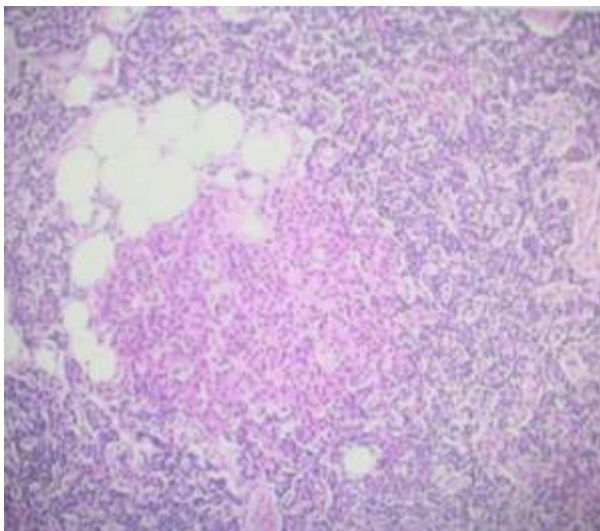
Email: dr\_sherinwagih@hotmail.com



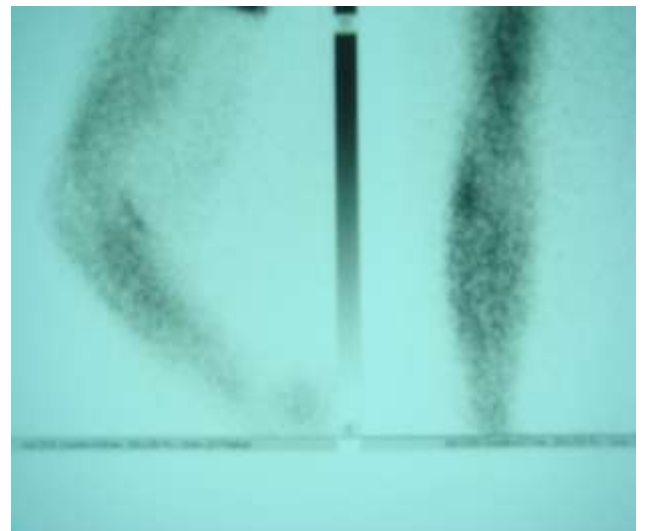
**Fig 1:** TL201 image (August 2010) of the right forearm showing TL201 avid lesion in upper outer aspect of right forearm ( upper row: Images with three radioactive marks around the lesion placed on the scar, olecranon process and in mid anticubital fossa -Lower row: no radioactive marks with well defined TL201 avid lesion in proximal lateral aspect of right forearm).



**Fig 2:** TL 201 Neck and mediastinal image showing normal myocardial activity with no definite TL201 avid lesions neither in the neck nor in the mediastinum.



**Fig3:** Parathyroid hyperplasia in secondary hyperparathyroidism with little or no adipose tissue, all cell types normally found in parathyroid are seen with pink oxyphil cells.



**Fig 4:** TL201 scan of right forearm showing linear TL201 avid lesion in proximal lateral aspect of right forearm representing recurrent parathyroid hyperplasia (Jan. 2011)

## Discussion

Secondary hyperparathyroidism is one of the most serious complications in long term haemodialysis patients with chronic renal failure (1). It occurs as a result of hypocalcemia due to end organ resistance to PTH with resultant stimulation of PTH production. This mechanism will generally result in hyperplasia of all parathyroid glands. Hyperparathyroidism is being diagnosed more frequently and earlier with the advent of automated serum analyzers for routine chemistry profiles, in fact over 80% of the patients with hyperparathyroidism have hypercalcemia as their own manifestation prior to any clinical symptoms or have only non specific symptoms. The remaining patients present with one or more symptoms of hypercalcemia. These symptoms are denoted by the mnemonic, painful bones, renal stones, abdominal groans and psychic moans, indicating the wide range of systemic effects of hypercalcemia (2,3). In patients with chronic renal failure associated with hypercalcemia serum PTH level should be estimated and its inappropriate elevation in relation to simultaneously elevated serum calcium level confirms the diagnosis of hyperparathyroidism. Actually the patient reported here had chronic renal failure with secondary hyperparathyroidism attributed to hyperplasia of the four parathyroid glands. Patient was asymptomatic with accidentally discovered hypercalcemia and elevated serum PTH level confirmed the diagnosis.

Despite advances in dialysis technique and pharmacologic therapy for secondary hyperparathyroidism in patients with chronic renal failure parathyroidectomy with or without autotransplantation of parathyroid tissue into the muscles of the neck or forearm is still performed in approximately 2% of patients annually (4). Surgery is seldom

needed except in cases of calciphylaxis, persistent hypercalcemia and severe symptoms such as bone pain, pruritis, muscle weakness, soft tissue pain from progressive calcification and spontaneous fractures (5). Also, surgery is indicated with elevated serum PTH level associated with hypercalcemia and hyperphosphatemia refractory to medical treatment (1). The latter was the reason for surgical intervention in the case reported in this article. Total parathyroidectomy means removal of the four parathyroid glands. While parathyroid reimplantation is performed in the same setting through putting of 10-20 small 1mm fragments into their individual pockets made in sternocleidomastoid or brachioradialis muscle in the non dominant forearm (the right side in our patient). The forearm is more favorably chosen for implantation as it is more readily accessible for later removal of parathyroid pieces in patients with persistent or recurrent hyperparathyroidism and it is easier for venous sampling to test for viability. Also, sutures or clips can be placed at implantation site for later identification. This technique of total parathyroidectomy and reimplantation is more favorable than subtotal parathyroidectomy (removal of 3.5 glands) because of significant risk of recurrent hyperparathyroidism in parathyroid neck remnant (6,7). This favored technique was done for our patient in the first surgical procedure (July 2009). No data about post surgical venous sampling from both forearms were available (mostly not done) and no sutures or clips were applied to localize site of implantation. Recently this ideal surgery (total parathyroidectomy and reimplantation) for patients with chronic renal impairment and secondary hyperparathyroidism can be performed using new surgical approach, In 2009 Sun et al concluded that endoscopic total parathyroidectomy with transplantation is a safe option for the treatment of secondary

hyperparathyroidism with low morbidity and mortality, short hospital stay and low recurrence rate.(1)

As a matter of fact the practice of implanting parathyroid tissue has a long surgical tradition, the main indication for this technique is secondary hyperparathyroidism. The high success rate of this autotransplantation is due to the ability of parathyroid tissue to induce angiogenesis (8). The time necessary to develop function in transplanted tissue is difficult to ascertain. A small PTH gradient between PTH level in venous blood of both forearms was apparent at 3 weeks but 12 to 18 weeks were required to reach normal peripheral levels(9). Another study done by Sippel et al (5) stated that normal parathyroid tissue resumed function 2-4 weeks after reimplantation and became fully functioning at 8 weeks.

In patients undergoing successful surgery for secondary or tertiary hyperparathyroidism 5-8% experience recurrence (10). This is comparable to 5-10% recurrence rate reported by Brennan and Norton, 1985 (11). Recurrence is most likely caused by hyperplasia of the small fragments of parathyroid tissue implanted in the forearm muscles. Fragment auto-transplant hyperplasia is an unusual event (5). Other causes of recurrence may be related to aberrant or ectopically located glands (11). Recurrent hyperplasia represents what happened to our patient after first removal of reimplanted tissue followed by normalization of serum calcium and parathormone levels. The treatment of forearm graft hyperplasia involves resection of the majority of hyperplastic parathyroid fragments, yet, the number of parathyroid fragments that need to be resected to achieve cure is often unpredictable and so recurrence can occur (5). First forearm Surgery (November 2009) was

done to the patient in another hospital without preoperative localization methods and with no sutures or clips placed at implantation site. This surgery was followed by normalization of serum levels of calcium and PTH (Jan.2010). Recurrence occurred due to hyperplasia of remnant implanted parathyroid fragments. Recurrence was diagnosed by positive laboratory data and overfunctioning parathyroid tissue was properly localized using CT scan and functionally characterized by TL201 scintiscans, necessitating resurgery in the forearm. The latter was done in September,2010 and post operative histopathology confirmed the diagnosis.

Persistent hypercalcemia postoperatively may be due to missed parathyroid gland at an abnormal location, persistent hyperparathyroidism from the residual parathyroids, incorrect pre operative diagnosis (malignancy), technical problems such as incomplete excision of sufficient amount of hyperplastic glands to achieve cure. Actually, dissection of the forearm can be problematic and it is difficult to determine if parathyroid tissue that has been removed is enough or not (5). Insufficient excision may be responsible for persistent hypercalcemia and non normalization of serum PTH level in our patient after second removal of reimplanted parathyroid tissue in the forearm(9-2010). Failure of normalization of serum calcium and PTH levels indicated persistent overfunctioning parathyroid tissue and necessitates rescanning with TL201 that revealed persistent overfunctioning parathyroid tissue in the forearm that was removed surgically in January 2011 and proved to be parathyroid hyperplasia. This latter surgery mostly removed sufficient parathyroid tissue to achieve normalization of biochemical data for up to nine months postoperatively. It is widely agreed that preoperative localization studies in parathyroid surgery are essential prior to reoperation because of the increased risk of

operating in a previously operated field and the likelihood of abnormal gland location. So, in patients with recurrent or persistent disease it is required to exhaust all localization procedures before exploration. Chou et al,2002 reported that for patients with persistent or recurrent hyperparathyroidism it is a great challenge to localize the hyperfunctioning parathyroid tissue ,whether it represents neck remnant or transplanted parathyroid tissue, prior to resurgery (12) . Scintigraphy is an ideal method to determine whether such recurrences are graft dependent or not because either TL201 or Tc99m MIBI can localize and functionally characterize the reimplanted parathyroid tissue (6).This was the concept for this particular patient, In addition to laboratory data confirming the presence of hypercalcemia and elevated serum PTH level, CT scan of the forearm was done and revealed presence of soft tissue lesion of 29X11.6X7.7mm. This means that if it is hyperplastic parathyroid tissue it will be excellently detected by scintiscans whether using TL201 or Tc99m MIBI due its size, and actually this was the case where this lesion showed high avidity to TL201 (Fig1). More importantly it excludes presence of overfunctioning parathyroid tissue neither in the neck nor in the mediastinum Fig2). This role of TL 201 scanning was greatly valuable for our patient prior to second and third forearm surgery , where it functionally characterized the lesion and showed that hyperparathyroidism is graft dependent in both occasions. Also, it promptly excluded the presence of any overfunctioning parathyroid tissue neither in the neck nor in the mediastinum. Patient achieved cure post excision of adequate amount of reimplanted parathyroid tissue. Sippel et al 2003, reported one patient with recurrent hyperparathyroidism with no surgical sutures or clips fixed for localization, yet, they were able to avoid negative neck exploration by using the radioguided technique using Tc99m MIBI

injection and intraoperative gamma probe to localize parathyroid fragments in the forearm muscles. They reported that intraoperative radioprobe with the injection of Tc99m MIBI allowed quick identification and removal of the abnormal parathyroid tissue in a case that was made particularly challenging by absence of marking sutures (5).

To our knowledge , this is the first report in which TL201 scanning can diagnose and functionally characterize multiple recurrences in implanted parathyroid tissue in the forearm post total parathyroidectomy in a patient with secondary hyperparathyroidism due to chronic renal failure.

## References:

- 1-Sun Y,Cai H,Bai J, Zhao H, Miao Y.: Endoscopic total parathyroidectomy and partial parathyroid tissue autotransplantation for patients with secondary hyperparathyroidism: a new surgical approach. *World J Surg.*Aug;33(8):1674-9,2009.
- 2-Talpos GB, Bone HG , Kleerekoper M et al: Randomized trial of parathyroidectomy in mild asymptomatic primary hyperparathyroidism: patient description and effects of the SF-36 health survey.*Surgery*;128:1013-1020.2000.
- 3-Weigel RJ: Non operative management of hyperparathyroidism: present and future. *curr Opin Oncol*;13;33-38.2001.
- 4-Decker PA, CohenEP, Doffek KM et al: Subtotal parathyroidectomy in renal failure: still needed after all these years. *World J Surgery*;25:708-712,2001.
- 5-Sippel SR, Bianco J., Chen H.: Case Report: Radioguided parathyroidectomy for recurrent hyperparathyroidism caused by forearm graft hyperplasia. *Journal of bone and mineral research.* Vol.18,Number5: 939-942,2003.

**6-**McCall AR, Calandra D, Lawrence AM et al : Parathyroid autotransplantation in forty-four patients with primary hyperparathyroidism: the role of thallium scanning. *Surgery*;4:614-620,1989.

**7-**Lo YC. and Tam CS.: Parathyroid autotransplantation during thyroidectomy: Documentation of graft function. *Arch Surg* Vol;136:1381-1385,2001.

**8-** Carter WB., Uy K, Ward MD, Hoying JB: Parathyroid induced angiogenesis is VEGF dependent. *Surgery*;128:458-464,2000.

**9-**Mallette LE, Eisenberg k, Wilson H, Noon GP.: Generalized primary parathyroid hyperplasia: studies of the evolution of autogenous parathyroid graft function. *Surgery*;93:254-259,1983.

**10-** Gasparri g, Camandona M, Abbona GC et al: secondary and tertiary hyperparathyroidism: causes of recurrent disease after 446 parathyroidectomies. *Ann Surg*;233:65-69,1986.

**11-**Brennan MF and Norton JA: Reoperation for persistent and recurrent hyperparathyroidism. *Ann Surg*;201:221-244,1985.

**12-**Chou F., Lee C., Chen H., Chen J., Hsu K. and Sheen-chen S. : Persistent and recurrent hyperparathyroidism after total parathyroidectomy with autotransplantation. *Ann Surg*;235(1):99-104,2002.