

**Original Article, Brain**

# Role of Brain Perfusion SPECT in the Assessment OF Neuropsychiatric Systemic Lupus Erythematosus

Zaher,A.<sup>1</sup> Abdellatif, S.<sup>2</sup> Eldahan, M.<sup>2</sup> Abdelazeem, E.<sup>2</sup>  
Elsayed,M.<sup>2</sup> Abdulmageed,Y.<sup>2</sup> and Farag, H.<sup>1</sup>

<sup>1</sup>Nuclear medicine dept. National Cancer Institute, Cairo University. <sup>2</sup>Rheumatology Dept. Al-Azhar University.

**ABSTRACT:**

Systemic lupus erythematosus (SLE) is an autoimmune disease with a broad variety of clinical manifestations, particularly affecting the kidneys and the central nervous system (NPSLE). In SLE, CNS manifestations have been described in 18-61% of patients which have a strong impact on morbidity and mortality. In patients with NPSLE, clinical signs and symptoms are focal in 25% and diffuse in the remaining patients. CT or MRI are useful in the detection of focal neurological deficits rather than diffuse presentations. Brain perfusion SPECT is a functional, noninvasive imaging modality. for many neurological and psychiatric conditions, used in diagnosis, prognosis assessment, evaluation of response to therapy, risk stratification, and choice of medical or surgical therapy. **The aim of this study** is the assessment of NPSLE using Tc-99m HMPAO brain perfusion SPECT. **Patients & Methods:** This study was carried out on twenty patients with SLE. The patients were classified into two groups: **Group1:** Patients without

neuropsychiatric manifestations(5patients).

**Group 2:** Patients with neuropsychiatric manifestations (15 patients) who have one or more of the CNS syndromes observed in SLE according to the American college of Rheumatology. All patients performed brain perfusion SPECT which was interpreted for focal or diffuse perfusion defects. **Results:** Five patients (25%) showed normal SPECT study while fifteen patients (75%) had positive findings (perfusion defects). Ten patients (66.6 %) had diffuse perfusion defects, while the other five patients (33.4 %) had focal perfusion defects patients the most common site of hypoperfusion was the parietal lobe. **Conclusion:** Brain Perfusion SPECT is a sensitive non invasive diagnostic imaging modality for detection of cerebral blood flow abnormalities in SLE patients, reflecting sequelae of vasculitis. It is also useful in evaluating CNS involvement in patients with minor neuropsychiatric manifestations with significant correlation between SPECT findings and disease activity.

## INTRODUCTION:

Systemic lupus erythematosus (SLE) is a prototype of an autoimmune disease with a broad variety of clinical manifestations, particularly affecting the kidneys and the central nervous system. In SLE, central nervous system (CNS) manifestations have been described in 18-61% of cases<sup>[1]</sup> which have a strong impact on morbidity and mortality<sup>[2]</sup>.

The American College of Rheumatology (ACR) has published case definitions for 19 neuropsychiatric SLE (NPSLE) syndromes, with careful criteria developed for research purposes and can be helpful to clinicians with a patient who has nervous system dysfunction<sup>[3]</sup>. Computed tomography (CT) or magnetic resonance imaging (MRI) has been found to be useful in the detection of focal neurological deficits rather than diffuse presentations<sup>[4]</sup>. MRI may be negative despite overt neuro psychiatric symptoms<sup>[5]</sup>. In patients with NPSLE, clinical signs and symptoms are focal in 25% and diffuse in the remaining patients. In patients with focal symptoms, neuro imaging modalities often reveal brain infarctions that are attributed to increased coagul ability resulting from the presence of ant phospholipid antibodies. In patients with diffuse symptoms, conventional MR images fail to demonstrate abnormalities that provide an explanation for these symptoms<sup>[6]</sup>. However, by using advanced techniques such as proton MR Spectroscopy, single photon emission CT (SPECT), positron emission tomography (PET), T2 relaxometry, and magnetization transfer imaging (MTI), cerebral abnormalities are found in patients with NPSLE<sup>[7]</sup>.

The central nervous system (CNS) may be affected by a focal or generalized vasculopathy or as a secondary consequence of the primary disease. A focal cerebral vacuities event may result in a stroke like presentation with an acute neurological deficit, a severe headache due to hemorrhage, focal seizures or optic neuropathy. A generalized vacuities event may result in diffuse cognitive changes, headaches, or seizures<sup>[8]</sup>.

The focal symptoms in NPSLE may be directly related to vascular lesions, whereas the more global manifestations may be related to autoantibody-mediated or cytokine-mediated impairment of the neuronal function<sup>[9]</sup>.

Brain SPECT, in particular, with perfusion agents or with neuro-receptor imaging radiopharmaceuticals, is rapidly becoming a clinical tool in many places. For many neurological and psychiatric conditions, this imaging modality has been used in diagnosis, prognosis assessment, evaluation of response to therapy, risk stratification, and choice of medical or surgical therapy<sup>[10]</sup>.

The brain perfusion imaging agents <sup>99m</sup>Tc-HMPAO and <sup>99m</sup>Tc-ECD are sensitive indicators of regional cerebral blood flow (r CBF) changes and can detect a reduction in blood flow immediately after an acute event. No other imaging modality currently has such a capability, despite considerable progress in the evaluation of cerebral blood flow with MRI over the past several years. Brain SPECT in psychiatric disorders is still investigational. Despite considerable research interest in this area, specific perfusion patterns of the various diseases

have not been definitely recognized. However, perfusion and receptor imaging findings may be used as an additional diagnostic tool to guide clinicians searching for a definite diagnosis<sup>[10]</sup>.

### **AIM OF THE WORK:**

Is the assessment of neuropsychiatric systemic lupus erythematosus using Tc-99m HMPAO brain perfusion SPECT.

### **PATIENTS AND METHODS:**

This study was carried out on twenty patients with SLE fulfilling at least 4 of the American College of Rheumatology criteria for the classification of SLE<sup>[11]</sup> (b) selected from the outpatient clinic of rheumatology department, Elhusein hospital over a period of 1.5 years. They included one male and 19 females with age ranging from 18 to 48 with a mean of 33 years.

The patients were classified into two groups:

**Group 1:** Patients without neuropsychiatric manifestations (5 patients).

**Group 2:** Patients with neuropsychiatric manifestations (15 patients) who have one or more of the CNS syndromes observed in SLE. Patients with neuropsychiatric manifestations that are secondary to other factors (such as uremia, hypertension or infection) were excluded.

Group 2 was further subdivided into two subgroups according to the classification proposed by<sup>[12]</sup>. Patients with major neuropsychiatric manifestations (e.g., stroke syndromes, severe organic brain syndrome, seizures, psychotic episodes, etc.) and Patients with minor neuropsychiatric manifestations including

mood disorders and less severe cognitive deficits.

Patients were subjected to Careful history taking, Complete clinical and neurological examination and Brain perfusion SPECT with Tc-99m HMPAO. Brain perfusion SPECT was done at the nuclear medicine department, National Cancer Institute, Cairo University using dual head gamma camera (SIEMENS, E – CAM). <sup>99m</sup>Tc-hexamethylpropyleneamine oxime (<sup>99m</sup>Tc-HMPAO) was prepared according to the manufacturer`s recommendation. Patients were injected in a quiet room with dimmed light and were allowed to relax for 15 minutes prior to intravenous administration of 20mCi<sup>99m</sup>Tc-HMPAO. SPECT acquisition was obtained using 128 x 128 matrix over 360 degree rotation, time per view 50 sec., number of views 32 and magnification 1.23. Images were reconstructed by filtered back projection using Butterworth filter with a cutoff frequency ~ 4.5. Images were displayed in transverse, coronal and sagittal slices in the ten degree color scale with the cerebellum adjusted at 100 %. Images were interpreted for focal or diffuse areas of hypo perfusion.

### **RESULTS:**

Clinically, 20 patients were suffering from arthralgia, 18 Patients had malar rash, 16 Patients had arthritis, 15 Patients had neuropsychiatric manifestations, 13 Patients developed alopecia and 10 Patients had oral ulcers. Among the whole patients group, five patients (25%) showed normal SPECT study, while fifteen patients (75%) had positive findings (perfusion defects). There was a significant difference between group (1)

(No NPSLE) and group (2) (NPSLE) as regards SPECT findings. Among the patients with abnormal SPECT findings, ten patients had diffuse perfusion defects as seen in fig 1, while the other five patients had focal perfusion defects seen in Fig 2 with focal hyper fusion in left pariently region. As regard the Systemic Lupus Erythematosus Disease Activity

Index (SLEDAI) there was a significant difference between SPECT positive and SPECT negative patients as noticed in table (1). Concerning the frequency of different sites of hypo perfusion in SPECT the most common site of hypo perfusion was the parietal lobe in 13 patients, followed by the temporal and occipital lobes.

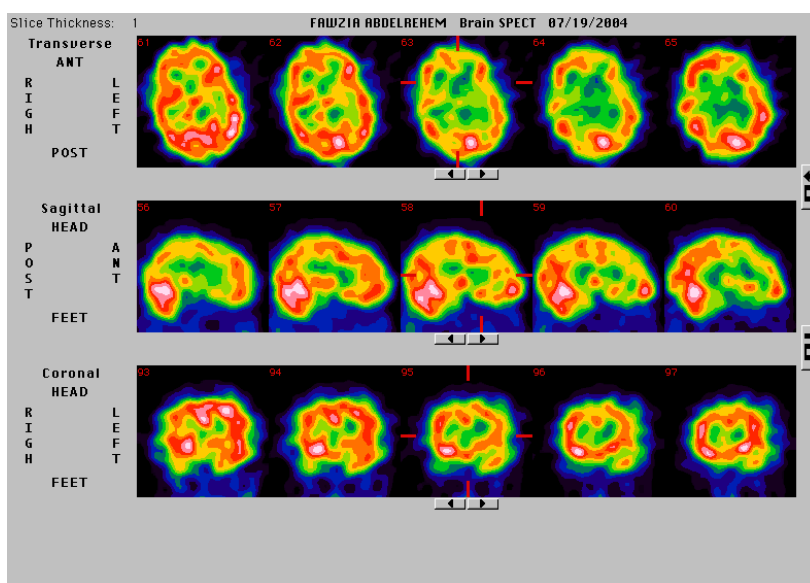


Fig 1: Diffuse patchy hypoperfusion involving both frontal and parietal lobes.

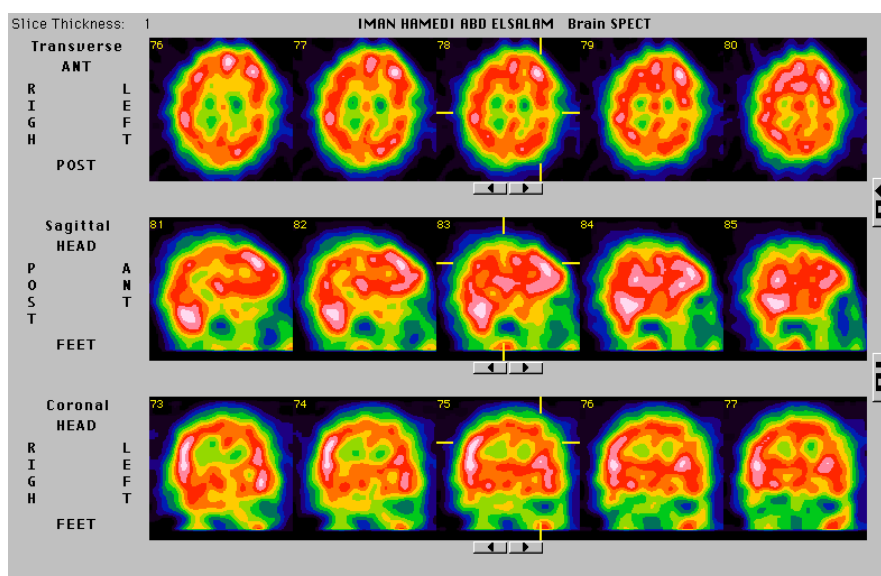


Fig 2 : Focal hypoperfusion involving the left parietal lobe.

**Table (1): SLEDAI in SPECT positive and SPECT negative patients**

	SLEDAI			P value
	Min.	Max.	Mean $\pm$ SD	
SPECT +ve	10	42	22.73 $\pm$ 10.69	p < 0.05
SPECT -ve	9	25	16.4 $\pm$ 5.85	

**DISCUSSION:**

Neuropsychiatric syndromes associated with systemic lupus erythematosus are common, but diverse in etiology and presentation<sup>[13]</sup>.

A variety of imaging techniques have been used in assessment of NPSLE. Functional evaluation of the CNS with SPECT has proven to be more sensitive in detecting CNS abnormalities than morphological studies, as the assessment of regional cerebral blood flow usually provides useful diagnostic information in the evaluation of NPSLE<sup>[14]</sup>.

As vasculitis processes are the mechanisms of cerebral symptoms in SLE, determination of r CBF as an indicator of CNS involvement seems promising<sup>[15]</sup>.

In the present study, SPECT was positive in 15 out of 20 patients (75%) with SLE. Similar results were reported by<sup>[16]</sup>

Who found areas of hypo perfusion on SPECT study in 17 out of 20 patients (85%) with NPSLE? Also the study done by<sup>[17]</sup> showed that 21 out of 25 patients (84%) with NPSLE had areas of hypo perfusion in SPECT study.

In addition,<sup>[22]</sup> showed that 12 out of 14 patients (85.7%) with NPSLE had. Abnormal SPECT. Also, in the study by<sup>[18]</sup>, SPECT scan was done in 11 patients with NPSLE and showed a very high sensitivity of 100 %. On the other hand,<sup>[19]</sup>, showed relatively low positive SPECT results (69% of patients with NPSLE).

Thus our study confirmed the previous assumption that SPECT is a sensitive tool in detecting abnormalities in NPSLE.

In the present study, areas of hypo-perfusion either focal or diffuse have been found in patients with SLE with major and minor neuropsychiatric disorders. All patients with major CNS manifestations showed abnormal scans, while 8 of 10 patients with minor CNS manifestations had abnormal SPECT. Similar result was repeated by<sup>[19]</sup> in their study including 10 patients with major and 15 with minor CNS manifestations. Nine patients with major involvement (90%) had abnormal SPECT, while 11 out of the 15 patients with minor involvement (73%) showed abnormal scan. Our results were also in agreement with those of<sup>[19]</sup>, where abnormal SPECT was found in 100% of patients with major neuropsychiatric manifestations and in 84.6 % of patients with minor neuropsychiatric manifestations.<sup>[22]</sup> reported abnormal scans in 93% of patients with major neuropsychiatric manifestations and in 69% of patients with minor neuropsychiatric manifestations. They documented that SPECT scanning seems to provide useful objective diagnostic information in SLE patients. In this study, the SPECT abnormalities were diffuse hypo perfusion in 66.6% and focal in 33.4% of cases. These findings agreed with<sup>[20]</sup> who reported that the most frequent abnormality in SPECT scan is multiple

foci of decreased uptake that was interpreted as areas of cerebral hypo perfusion. The frequency of scan abnormalities is higher in patients with diffuse than those with focal disease. The detection of SPECT scan abnormalities (i.e. areas of hypo perfusion either focal or diffuse) in the absence of NPSLE is of particular interest, since these abnormalities may reflect subclinical CNS involvement that could progress to severe neuropsychiatric manifestations. The frequency is highly variable ranging from 70 - 80 % in some reports<sup>[21]</sup> to 10 % in others (Kodama et al., 1999).

### CONCLUSION:

Brain Perfusion SPECT is a sensitive non invasive diagnostic imaging modality for detection of cerebral blood flow

### REFERENCES:

1. **Sibley JT, Olszynski WP, Decoteau WE, Sundaram MB.** The incidence and prognosis of central nervous system disease in systemic lupus erythematosus. *J Rheumatol* 1992; 19:47-52.
2. **Neuwelt CM, Lacks S, Kaye BR, Ellman JB, Borenstein DG.** Role of intravenous cyclophosphamide in the treatment of severe neuropsychiatric systemic lupus erythematosus. *Am J Med* 1995; 98:32-41.
3. **Hermosillo-Romo D, Brey RL.** Neuropsychiatric involvement in systemic lupus erythematosus. *Curr Rheumatol Rep.* 2002 Aug; 4 (4):337-44.
4. **West SG, Emlen W, Wener MH, Kotzin BL.** Neuropsychiatric lupus erythematosus: a 10-year prospective study on the value of diagnostic tests. *Am J Med* 1995; 99:153-163.
5. **Weiner SM, Otte A, Schumacher M, Klein R, Gutfleisch J, Brink I, et al.** Diagnosis and monitoring of central nervous system involvement in systemic lupus erythematosus: value of F-18 fluorodeoxyglucose PET. *Ann Rheum Dis* 2000; 59:377-85.
6. **Kozora E, Thompson L, West S, et al.:** Analysis of cognitive and psychological deficits in systemic lupus erythematosus patients without overt central nervous system disease. *Arthritis Rheum* 1996, 39:2035-2045.
7. **BosmaGPT, Rood MJ, Zwinderman AH, Huizinga TWJ, Van Buchem MA.** Evidence of CNS damage in patients with neuropsychiatric systemic lupus erythematosus demonstrated by magnetization transfer imaging. *Arthritis Rheum* 2000; 43:48-54.
8. **Rosenbaum R:** Neuromuscular complications of connective tissue diseases. *Muscle Nerve* 2001, 24:154-169.

In the present study, according to the SLEDAI there was a significant difference between SPECT positive and SPECT negative patients. These results agree with<sup>[22]</sup>, as they found significant difference between disease activity among SPECT positive and SPECT negative patients.

In this study there was no significant difference as regard the site of the involved area. This finding agreed with<sup>[22]</sup> who found no significant difference regarding the involved area.

abnormalities in SLE patients with significant correlation between SPECT findings and disease activity.

9. **Katzav A, Chapman J, Shoenfeld Y:** CNS dysfunction in the antiphospholipid syndrome. *Lupus* 2003, 12:903-907.
10. **Edwaldo E. Camargo,** Brain SPECT in Neurology and Psychiatry, *Journal of Nuclear Medicine* Vol. 42 No. 4 611-623.
11. **ACR** ad hoc committee on neuropsychiatric lupus nomenclature. The American College of Rheumatology nomenclature and case definitions for neuropsychiatric lupus syndromes. *Arthritis Rheum* 1999; 42:599–608.
12. **How, et al.,** 1985 Bombardier C, Gladman DD, Urowitz MB, Caron D, Chang CH. Derivation of the SLEDAI. A disease activity index for lupus patients. The Committee on Prognosis Studies in SLE. *Arthritis Rheum.* 1992 Jun; 35 (6): 630-40.
13. **Melanie J. Harrison, MD, MS, Lisa D. Ravdin,** PhD Cognitive Dysfunction in Neuropsychiatric Systemic Lupus Erythematosus *Curr Opin Rheumatol* 2002; 14 (5): 510-514.
14. **Colmussi P., Doninger N.A. and Zee P.C.:** Factors influencing cognitive function, sleep and quality of life in individuals with systemic lupus erythematosus. *Curr Opin Rheumatol* 1994; 16: 481 – 486.
15. **Stefan H., Bauer J., and Huk W.J.:** Regional CBF during focal seizure of temporal and frontocentral onset. *Ann. Neurol* 1990;. 27: 162 – 166.
16. **Nossent J.C., Hovestadt A., Schonfield D.H. et al:** Single photon emission computed tomography of the brain in the evaluation of cerebral lupus. *Arthritis Rheum*, 1991; 34: 1397 – 1403.
17. **Rubbert A., Marienj H. J., Pirner K. et al:** Single photon emission computed tomography analysis of cerebral blood flow in the evaluation of CNS involvement in patients with systemic lupus erythematosus. *Arthritis Rheum*, 1993; 36: 1253 – 1262.
18. **Reiff A., Miller J., Shaham B. et al:** Childhood CNS lupus: Longitudinal assessment using SPECT. *J Rheumatol*, 1997; 24: 2461 – 2465.
19. **Lin W. Y., Wang S.J. , Yen T. C. et al :** Brain SPECT in SLE with CNS involvement. *J Nucl Med* 1997; 38: 1112 – 1115,.
20. **Russo R. , Gilday D., Laxer R. M. et al:** SPECT scanning in childhood SLE. *J Rheumatol* 1998; 25 : 576 – 582.
21. **Emmi L., Bramati M., and Cristofaro M.:** MRI and SPECT investigations of the CNS in SLE patients. *ClinExpRheumatol*, 1999; 11: 13 – 20.
22. **Kikukawa K. , Toyama H. , Kataama M. et al :** Early and delayed brain SPECT in SLE patients with CNS involvement. *Ann Nucl Med*, 2000; 14: 25 – 32.